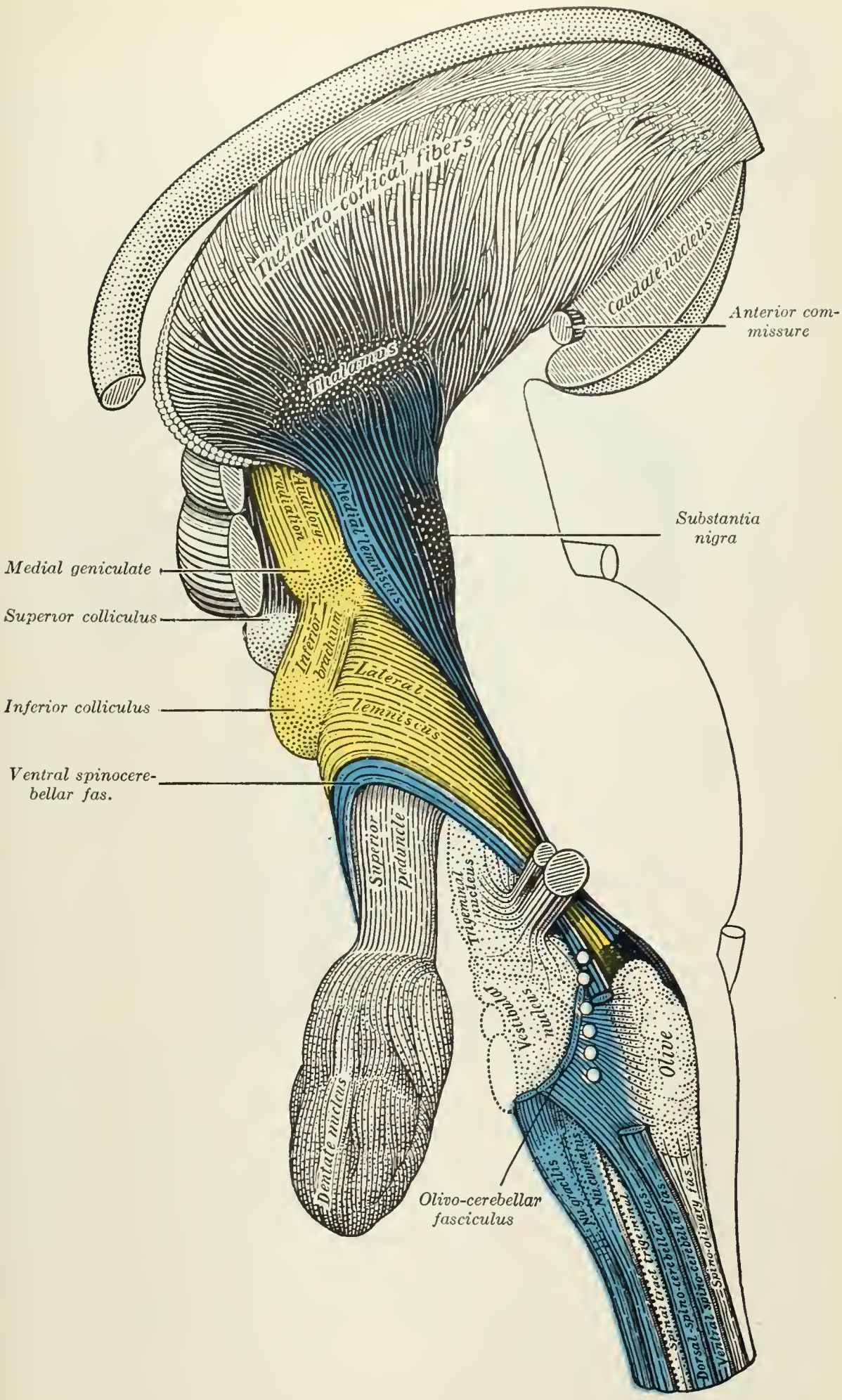

FIG. 685.—Deep dissection of brain-stem. Lateral view.