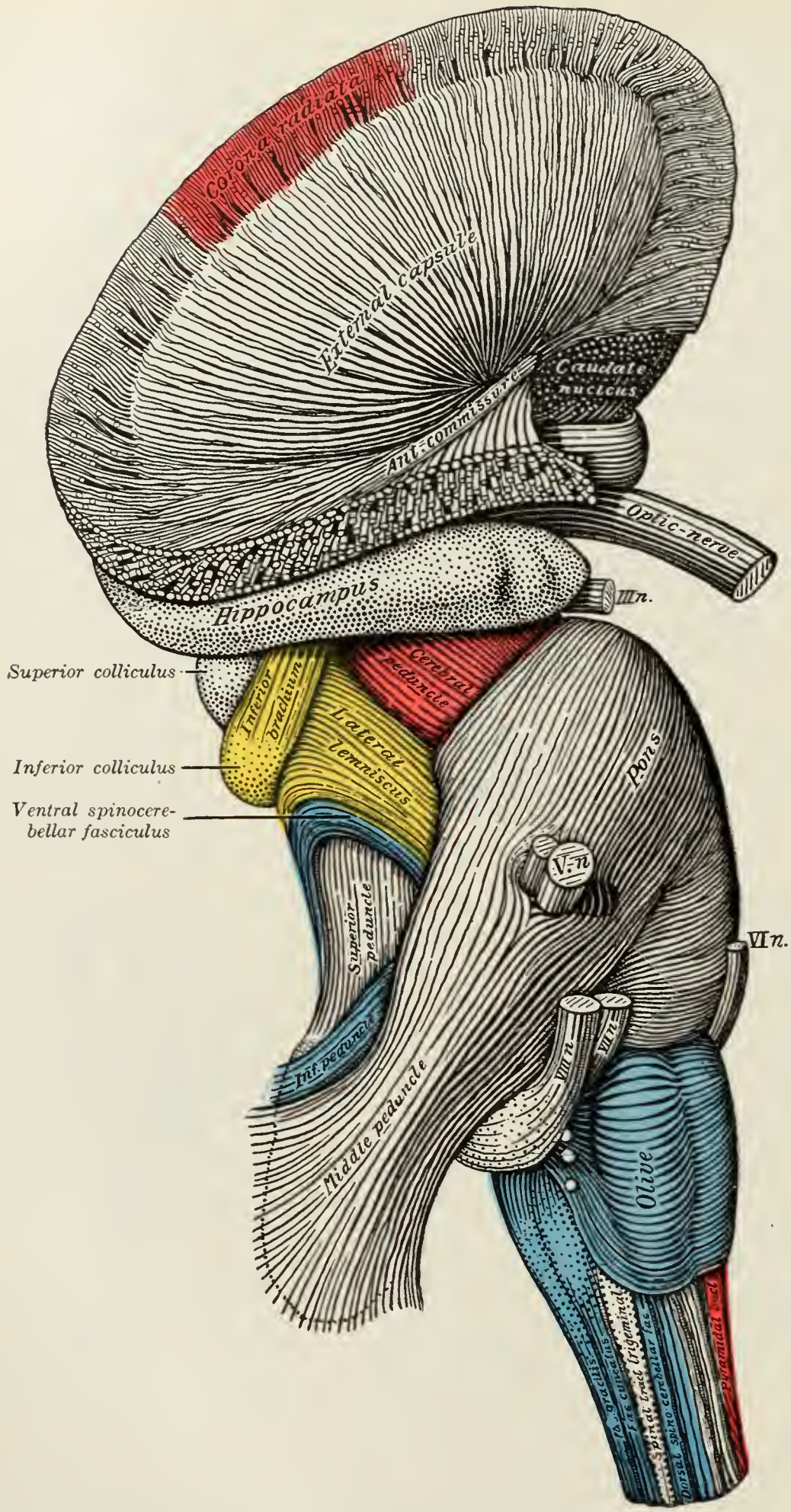

FIG. 682.—Superficial dissection of brain-stem. Lateral view.